

The Effect of Oculo-Acupuncture on Acute Hepatic Injury Induced by Carbon Tetrachloride in Dogs

Jianzhu Liu,* Sung-Nam Cho,† Kun-Ho Song,† Duck-Hwan Kim,†
Myung-Cheol Kim‡ and Sung-Whan Cho§

*Laboratory of Veterinary Internal Medicine, College of Animal Science and Veterinary Medicine
Shandong Agricultural University, Taian 271018, China

†Laboratory of Veterinary Internal Medicine, ‡Laboratory of Veterinary Surgery

§Laboratory of Veterinary Pathology, College of Veterinary Medicine
Chungnam National University, Daejeon 305-764, Korea

Abstract: We investigated the therapeutic effect of oculo-acupuncture on dogs induced with acute hepatic injury. Hepatic injury was induced by intraperitoneal injection with carbon tetrachloride (CCl₄) in 8 mongrel dogs (4 females and 4 males, aged 2 to 4 years). The dogs were divided into the control group (4 dogs) and the experimental group (4 dogs). The experimental group was treated with oculo-acupuncture at the liver/gallbladder regions plus the zhong jiao region of the eye after the induction of hepatic injury. Serum aspartate aminotransferase (AST), alanine aminotransferase (ALT), and gamma glutamyl transpeptidase (GGT) activities were measured in both control and experimental groups. The serum AST, ALT, and GGT activities in the experimental group were decreased as compared to those in the control group. The significant differences were detected on the third day (AST, $p < 0.05$), second day (ALT, $p < 0.05$) and third day (GGT, $p < 0.05$) in the experimental group, respectively. Oculo-acupuncture alleviated acute liver damage induced by carbon tetrachloride in dogs was also confirmed by histopathological examination. We concluded that oculo-acupuncture at the liver/gallbladder regions plus the zhong jiao region was effective in the recovery of dogs from hepatic injury in a CCl₄-induced model.

Keywords: Oculo-Acupuncture; CCl₄; Liver Injury; Dog.

Introduction

Acute liver failure is described as a clinical syndrome marked by the sudden onset of hepatic failure signs including cerebral edema, hemodynamic instability, renal failure, coagulopathy, metabolic disturbances, and susceptibility to bacterial and fungal infection (Williams and Riordan, 2002; Sherlock and Dooley, 2002). Acute liver failure is mostly induced by viral hepatitis, alcoholism, iron overload, or drug toxicity. This disease has a very high morbidity and mortality. Anti-inflammatory or antioxidant medicines have been used for the treatment of acute hepatic failure.

The successful use of traditional eastern medicine to counter human and animal diseases has been recently reported. This includes needle-acupuncture (AP) (Yung, 2004), injection-AP (Kim *et al.*, 2005; Lin *et al.*, 2002; Hong *et al.*, 2002; Hwang *et al.*, 2001; You *et al.*, 1997), electro-AP (Kim *et al.*, 2004; Lee *et al.*, 2004; Jang *et al.*, 2003), laser-AP (Hong *et al.*, 2002), hemo-AP (Chea, 1997) and moxibustion (Li *et al.*, 2004; Jang *et al.*, 2003).

Oculo-acupuncture (OA) is a new form of acupuncture therapy. Thirteen special points on eight parts around the eye's orbit are used (Zhao, 1997). The therapy is based on the ancient medical concept by Hua Tuo, a Han Dynasty physician, which involves diagnosing diseases by inspecting the eyes, and applying needles at acupoints around the eyeball and on the orbital edge to treat diseases. OA has good therapeutic effects on vomiting (Xiao, 1994; Zhao, 1995; Yang, 2001), acute muscular sprain (Zhang 1994; Fu 1996), apoplexy and hemiplegia (Li, 1995; Ren and Lin, 2005) and pain (Peng, 1990; Zhao, 1997). Zhao (1995) reported that OA had good therapeutic effects in 60 cases of human patients with vomiting. Furthermore, Fu *et al.* (2002) reported that the therapeutic effect of OA was better than that of body AP, and was similar to the therapeutic effect of drug medication in human patients with asthmas. Meanwhile, Wang *et al.* (2004) reported that OA treatment of the liver, heart and kidney regions could improve the symptoms of memory disorder, and could change the ultrastructure of hippocampus neurons which was found in the experimental vascular dementia induced in rats. Zhang and Shi (2002) reported that OA treatment of the liver, kidney and shang jiao regions could increase the therapeutic effect of the medication treatment on sudden deafness.

The therapeutic effects of OA have been studied in various human diseases in China. However, there is no report about its therapeutic effects on liver disease up to now. Hence, we aimed to investigate therapeutic effects of OA on the acute hepatic injury induced by carbon tetrachloride (CCl₄) in dogs.

Materials and Methods

Experimental Animals

Eight (4 males and 4 females) clinically healthy mongrel dogs with weight ranging from 2.2 kg to 4.0 kg, and aged 2 to 4 years were randomly selected for this study. The animals were kept individually in stainless cages. They were fed with balanced diet and were

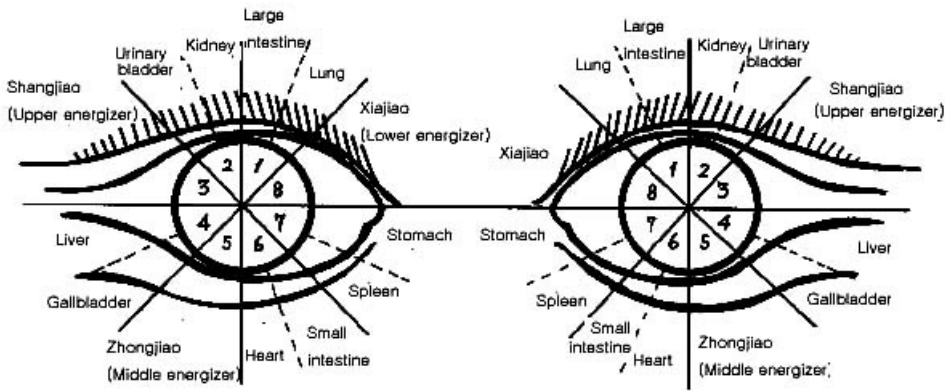


Figure 1. Acupoint of oculo-acupuncture (↑: Direction of the needle).

supplied with water *ad libitum*. The dogs were divided into the control group (4 dogs) and the experimental group (4 dogs). As for the treatment in each group, the control group did not receive any treatment, while the experimental groups were treated with OA at the liver and gallbladder regions plus the zhong jiao region of the eye after the hepatic injury was induced. The present study was performed according to the rules set for experimental animals by the Ethics Committee of Chungnam National University.

Induction of Hepatic Injury

Acute hepatic injury was induced by a single intraperitoneal injection of CCl_4 solution (CCl_4 : soybean oil = 1:1) with a volume of 1 ml/kg after sterilization.

OA Stimulation

This study involved acupoints at the liver and gall bladder regions, and the zhong jiao region of the eye according to human OA (Peng, 1990). The 13-mm needle (Hwato[®], Suzhao Medical Appliance Factory, China) was inserted into the liver and the gall bladder region (in an oblique direction from GB01), and the zhong jiao region (in a horizontal direction from ST01) (Fig.1). The AP needle was applied for 20 min once a day for five days.

Serum Samples and Analysis

Blood was collected from the cephalic vein of the dogs, and the serum was separated by centrifugation at 1800 g for 15 min. An automatic blood chemistry analyzer (SM-4000, B.S Biochemical Systems, Italy) was used for determining the serum concentrations of aspartate aminotransferase (AST), alanine aminotransferase (ALT), and gamma glutamyl transpeptidase (GGT).

Histopathologic Examination

Seven days after the hepatic injury and OA treatment, the dogs were euthanized after the commencement of the experiment by intravenous injection with pentobarbital sodium (Nembutal[®], Bando Pharmacological Co., Korea, 60 mg/kg, IV), and the liver tissue specimen was taken. The tissue specimen was fixed with 10% buffered formalin solution and processed tissue embedding. Thin paraffin sections were made and stained with hematoxylin-eosin (H&E) for light microscopic examination.

Statistical Analyses

The significant difference between the control and experimental groups was analyzed using paired student's t-test with a database (SPSS v. 12.0, K). $p < 0.05$ was statistical significance.

Results

Serum Enzymes Activities

Serum AST activities showed a gradual increase two days after CCl₄ injection and then a decreasing tendency in the control group. Serum AST activities in the experimental group had lower values than those in the control group, and a significant difference was found on the third day ($p < 0.05$) after OA in the experimental group (Fig. 2).

Serum ALT activities showed a peak increase one day after CCl₄ injection and then started to decrease in the control group. The serum ALT activities in both groups were initially similar. However, the experimental group had lower values than the control group. The serum ALT activities of the experimental group showed a significant decrease two days ($p < 0.05$) after OA treatment as compared to those of the control group (Fig. 3).

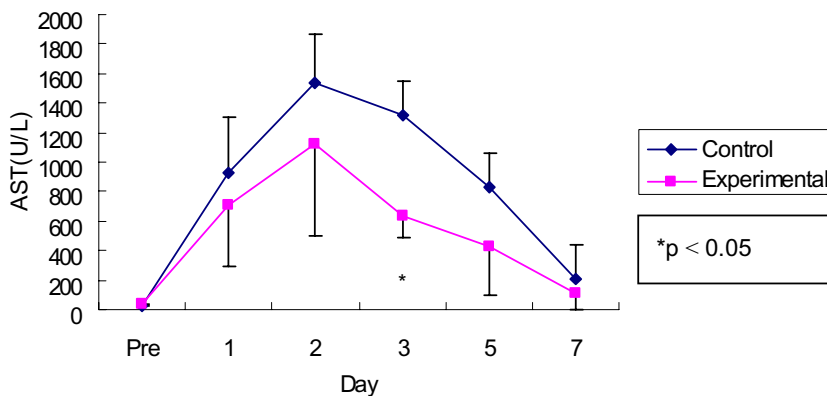


Figure 2. AST activities in oculo-acupuncture treatment and control groups.

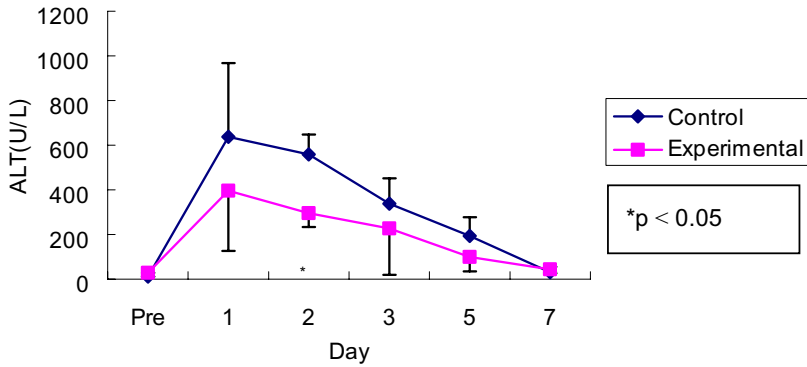


Figure 3. ALT activities in oculo-acupuncture treatment and control groups.

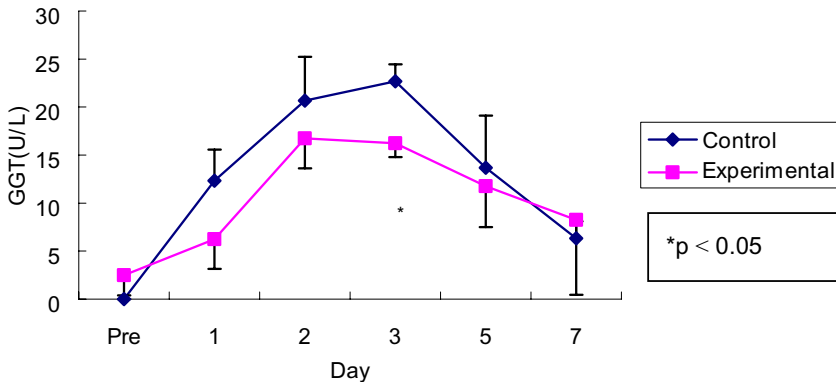


Figure 4. GGT activities in oculo-acupuncture treatment and control groups.

Serum GGT activities demonstrated a gradual increase three days after CCl₄ injection and then showed a decreasing tendency during the termination of this study in both groups. The serum GGT activities of the experimental group significantly decreased ($p < 0.05$) three days after OA as compared to those of the control group (Fig. 4).

Histopathologic Findings

The massive changes characterized by the necrosis of lobules and contiguous lobules were found in the liver seven days after CCl₄ injection in the control group (Fig. 5). On the other hand, mild hepatocytic degenerations of the liver were observed in the experimental group. As compared to the control group, hepatic injuries in experimental group were much alleviated histopathologically (Fig. 6).

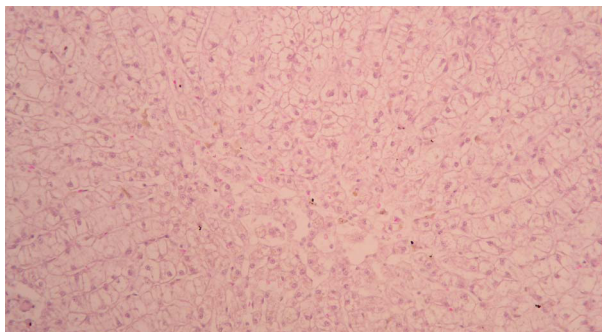


Figure 5. Diffuse vacuolar degeneration of the liver on the 7th day in the control group. (H and E; $\times 200$)

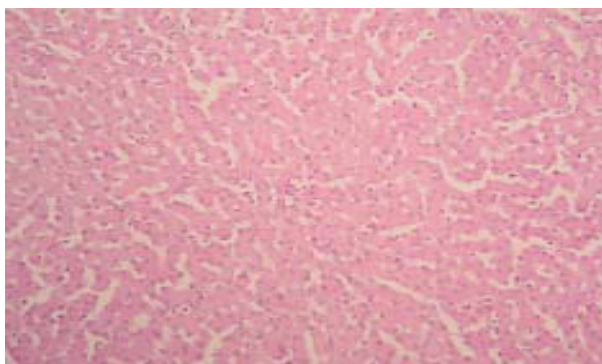


Figure 6. Mild hepatocytic degenerations of the liver on the 7th day in the oculo-acupuncture treatment group (H and E; $\times 200$).

Discussion

Acute hepatic injury is a serious and life-threatening clinical syndrome which is characterized by hepatic function damage due to the necrosis of a large amount of hepatocytes. Several drugs (Hussain *et al.*, 2003; Durazo *et al.*, 2004; Russo *et al.*, 2004) and some chemicals (Reddy *et al.*, 2004; Pawa *et al.*, 2004; Tzirogiannis *et al.*, 2004) can cause acute hepatic injury or failure due to massive hepatocytic necrosis. The clinical treatment of acute hepatic injury or failure is an urgent problem that needs to be solved. Since liver tissues perform important functions like complex metabolism, biological synthesis, biological transformation, detoxification, and excretion, the rapid development of massive hepatic necrosis and apoptosis may give rise to severe metabolic disorder and accumulation of poisons, which often lead to the failure of other organs. The disease has a poor prognosis with a mortality rate around 65% to 85%, and the death rate is about 95% if the patients with fulminant hepatic failure experience stage IV hepatic encephalopathy complications (Batra and Acharya, 2003).

AP treatment produces better therapeutic effects on various diseases than conventional treatment methods such as subcutaneous or intramuscular injection with the same drugs. Injection AP stimulates the acupoints continuously before the injected drugs are absorbed, and the absorbed drugs also induce their effects after absorption (Hong *et al.*, 2002; Hwang *et al.*, 2001; You *et al.*, 1997). Song *et al.* (2003) reported that injection AP with Korean ginseng saponin at BL-18 was more effective than intramuscular injection in rats induced liver damage. Meanwhile, You *et al.* (1997) reported that injection AP with liver tonics at BL-18 was more effective than intramuscular injection in healing induced liver damage in dogs. Hong *et al.* (2002) reported that injection AP with methionine at BL-18 was more effective than laserpuncture in healing induced liver damage in rats. Lee *et al.* (2004) also reported that auriculoacupoint (AAP) treatment had therapeutic effect on liver injury induced by CCl₄ in dogs. Our results revealed that eye AP treatment had a therapeutic effect on liver injury induced by CCl₄ in dogs.

As for the theory of OA, it is related with the eye and the meridians. The eyes are closely related to internal organs and meridians, and the acupuncture applied at the acupoints around the eye can be used to treat many bodily diseases (Zhao, 1997; Peng, 1990).

The acupoints which we selected in this study for OA were the liver and the gallbladder regions. Needle insertion was started at GB01-tong zi liao. It is the first acupoint in the gallbladder meridian, and is related with all the acupoints of the gallbladder (GB) meridian. The needle was inserted from ST01-cheng qi which is the first acupoint in the stomach (ST) meridian, and is related with all the acupoints of the stomach meridian in zhong jiao region. It was speculated that the present OA has some therapeutic effects on hepatic damage by means of the stimulation of the GB and ST meridians.

The biochemical parameters in the injured liver were significantly reduced by AP treatment after hepatic injury (Liu *et al.*, 2001; Lee *et al.*, 2004). As compared to those of the control group, the results of OA demonstrated that serum AST, ALT and GGT activities in the experimental group were significantly different on the third day ($p < 0.05$), second day ($p < 0.05$) and third day ($p < 0.05$), respectively, in the present study. It was considered that these changes were caused by the recovery of the hepatic tissues by OA.

On the histopathological features of the hepatic tissues in CCl₄ intoxication, Lee *et al.* (2004) and Sung *et al.* (1998) reported that the coagulative necrosis of the hepatic cells, the hemorrhage of the centrilobular and the midzonal region were observed after liver injury. The current study's results showed that massive changes characterized by the necrosis of lobules and contiguous lobules were found on the seventh day in the control group, while mild hepatocytic degenerations of the liver were observed in the experimental group. The alleviated findings for hepatic injury were very significantly different in the experimental group histopathologically. It was therefore assumed that the histopathological alleviated finding for the injured hepatic tissue backed up the therapeutic effect of OA.

In conclusion, we investigated the therapeutic effect of OA on dogs induced with acute hepatic injury. It was demonstrated that OA was effective in the recovery of damaged liver tissues induced by CCl₄ in dogs.

References

- Batra, Y. and S.K. Acharya. Acute liver failure: prognostic markers. *Indian J. Gastroenterol.* 22(Suppl. 2): S66–S68, 2003.
- Chea, W.S. *Wonderful Integration of Dong's Acupoint*, 1st ed. Ilzungsa, Seoul, Korea, 1997, pp. 251–380.
- Durazo, F.A., C. Lassman, S.H. Han, S. Saab, N.P. Lee, M. Kawano, B. Saggi, S. Gordon, D.G. Farmer, H. Yersiz, R.L. Goldstein, M. Ghobrial and R.W. Busuttil. Fulminant liver failure due to usnic acid for weight loss. *Am. J. Gastroenterol.* 99: 950–952, 2004.
- Fu, W.B., X.H. Chen and Q.X. Chen. Clinical observation on the control acute attack of deficiency-syndrome asthma with eye acupuncture. *Shang Hai Zhen Jiu Za Zhi* 21(5): 20–22, 2002.
- Fu, W.B. The eye acupuncture treats muscular sprain clinical observation. *Bei Jing Zhong Yi Yao Da Xue Xue Bao* 11: 34, 1996.
- Hong, M.S., J.Y. Lee, B. Lee, S.E. Lee, J.M. Seo, K.H. Song, D.H. Kim, K.W. Cho and M.C. Kim. The effect of laserpuncture and aquapuncture with methionine on the recovery in artificially induced hepatic damaged rats. *Kor. J. Vet. Clin.* 19: 125–131, 2002.
- Hussain, Z., P. Kar and S.A. Husain. Antituberculosis drug-induced hepatitis: risk factors, prevention and management. *Indian J. Exp. Biol.* 41: 1226–1232, 2003.
- Hwang, S.H., J.M. Seo, M.S. Hong, Y.S. Choi, K.H. Song, D.H. Kim, M.C. Kim and K.S. Shin. Immunomodulatory effect of aquapuncture with canine parvovirus vaccine. *Kor. J. Vet. Clin.* 18: 368–373, 2001.
- Jang, K.H., J.M. Lee and T.C. Nam. Electroacupuncture and moxibustion for correction of abomasal displacement in dairy cattle. *Kor. J. Vet. Res.* 4: 93–95, 2003.
- Kim, D.H., S.H. Cho, K.H. Song, S.E. Lee, S.H. Lee, G.O. Kwon, I.B. Kim, Y.C. Kim, J.H. Cho, Y.Y. Kwan and J.W. Kim. Electroacupuncture analgesia for surgery in cattle. *Am. J. Chin. Med.* 32: 131–140, 2004.
- Kim, H.W., Y.B. Kwon, H.J. Han, I.S. Yang, A.J. Beitz and J.H. Lee. Antinociceptive mechanisms associated with diluted bee venom acupuncture (apipuncture) in the rat formalin test: involvement of descending adrenergic and serotonergic pathways. *Pharmacol. Res.* 51(2), 183–188, 2005.
- Lee, S.E., K.H. Song, J. Liu, H.J. Kwon, S.B. Youn, Y.W. Lee, S.H. Cho and D.H. Kim. The effectiveness of auriculoacupoint treatment for artificially induced acute hepatic injury in dogs. *Am. J. Chin. Med.* 32(3): 445–451, 2004.
- Li, X.F. Eye acupuncture treatment apoplexy hemiplegia 36 cases. *Zhong Guo Min Jian Yi Xue Za Zhi* 5: 297, 1995.
- Li, Y., F.R. Liang, S.G. Yu, C.D. Li, L.X. Hu, D. Zhou, X.L. Yuan, Y. Li and X.H. Xia. Efficacy of acupuncture and moxibustion in treating Bell's palsy: a multicenter randomized controlled trial in China. *Chin. Med. J. (Engl.)* 117: 1502–1506, 2004.
- Lin, J.H., L.S. Wu, Y.L. Wu, C.S. Lin and N.Y. Yang. Aquapuncture therapy of repeat breeding in dairy cattle. *Am. J. Chin Med.* 30: 397–404, 2002.
- Liu, H.J., S.F. Hsu, C.C. Hsieh, T.Y. Ho, C.L. Hsieh, C.C. Tsai and J.G. Lin. The effectiveness of Tsu-San-Li (ST-36) and Tai-Chung (Li-3) acupoints for treatment of acute liver damage in rats. *Am. J. Chin. Med.* 29(2): 221–226, 2001.
- Pawa, S. and S. Ali. Liver necrosis and fulminant hepatic failure in rats: protection by oxyanionic form of tungsten. *Biochim. Biophys. Acta* 1688: 210–222, 2004.
- Peng, J.S. *Eye Acupuncture*. Liaoning Press of Science and Technology, China, 1990.
- Reddy, P.V., Ch.R. Murthy and P. Reddanna. Fulminant hepatic failure induced oxidative stress in nonsynaptic mitochondria of cerebral cortex in rats. *Neurosci. Lett.* 368: 15–20, 2004.

- Ren, X.Y. and Y.S. Lin. Eye acupuncture treatment apoplexy hemiplegia 30 cases effects observation. *Xian Dai Yi Xue* 4: 56–57, 2005.
- Russo, M.W., J.A. Galanko, R. Shrestha, M.W. Fried and P. Watkins. Liver transplantation for acute liver failure from drug-induced liver injury in the United States. *Liver Transpl.* 10: 1018–1023, 2004.
- Sherlock, S. and J. Dooley. *Disease of the Liver and Biliary System*, 11th ed. Oxford, Blackwell, 2002, pp. 111–126.
- Song, K.H., M.S. Hong, J.M. Seo, S.E. Lee, Y.W. Lee and D.H. Kim. Cases applied the electroacupuncture and combined therapy with electroacupuncture and aquapuncture for canine hind limb paralysis. *J. Vet. Med.* 56: 889–892, 2003.
- Sung, J.K., H.C. Lee, J.H. Yoon, Y.W. Lee, Y.J. An and H.J. Choi. Ultrasonographic and radiographic evaluation for the quantitative diagnosis of diffuse hepatic disease in dogs. *Kor. J. Vet. Res.* 38: 918–928, 1998.
- Tzirogiannis, K.N., G.I. Panoutsopoulos, M.D. Demonakou, G.K. Papadimas, V.G. Kondyli, K.T. Kourentzi, R.I. Hereti and M.G. Mykoniatzi. The hepatoprotective effect of putrescine against cadmium-induced acute liver injury. *Arch. Toxicol.* 78: 321–339, 2004.
- Wang, P.Q., L.P. Wang, F.W. Chao, J. Yu and J. Wang. The improving effect of eye acupuncture on learning disorder and dysmnnesia, and changes in the ultrasturcture of hippocampus neurons in experimental vascular dementia rats. *Shang Hai Zhen Jiu Za Zhi* 23(1): 41–44, 2004.
- Williams, R. and S.M. Riordan. Fulminant hepatic failure. In: Schiff, E.R., M.F. Sorrell and W.C. Maddrey (eds.) *Schiff's Disease of the Liver*, 9th ed. Lippincott Williams & Wilkins, Philadelphia, 2002, pp. 941–970.
- Xiao, S.J. Eye eyeacupuncture treatment stubbornness sickness vomits 2 cases. *Jiang Xi Yi Xue Yuan Xue Bao* 13: 100, 1994.
- Yang, S. The eye acupuncture treatment stubbornly vomits. *Zhong Guo Min Jian Liao Fa* 6: 26, 2001.
- You, M.J., D.H. Kim, S.W. Cho, W.K. Yun and K.D. You. The effect of aquapuncture with heptonics on the recovery in artificially induced hepatic damaged dogs. *J. Vet. Clin.* 14: 308–318, 1997.
- Yung, K.T. A birdcage model for the Chinese meridian system: part I. A channel as a transmission line. *Am. J. Chin. Med.* 32: 815–828, 2004.
- Zhang, Z. and J. Shi. Observation on the therapeutic effect of eye acupuncture for 42 cases of sudden deafness. *Zhong Guo Zhen Jiu* 22(8): 523–524, 2002.
- Zhang, C.Y. The eye acupuncture treats muscular sprain. *Hei Long Jiang Zhong Yi Xue* 6: 40, 1994.
- Zhao, F.Y. The eye acupuncture treats heavily sickness vomits the counter 60 cases clinical observation. *Gan Su Zhong Yi Xue Yuan Xue Bao* 13: 43, 1995.
- Zhao, X. *Eye Acupuncture*. Academy Press, China, 1997.